



PATIENT

Juice Lunas

SPECIES

Feline

BREED

DSH

SEX

Male Neutered

AGE

3.16.14

WEIGHT

14lbs

INTERPRETED BY

Maggie Machen Lamy,
DVM, DACVIM
(Cardiology)

IMAGING PERFORMED BY

Andi Parkinson, RDMS

HOSPITAL NAME

Chadwell Animal
Hospital

REFERRING VET

Dr. Gold

INVOICE

22675

DATE

2.18.22

PRESENTING CLINICAL SIGNS

History: Grade 4 murmur

-Pertinent abnormal PE/Chem/CBC/UA Results: Anemia (HCT 15).

-Current medications: Vetmedin/Methimazole.

-Sedation used: Not required to complete full diagnostic ultrasound.

-Pertinent previous ultrasound results: No previous IntraPet scans.

-STAT: Not requested.

ECHOCARDIOGRAM FINDINGS

2D, m-mode, color flow and doppler imaging is available. The left ventricular wall is largely normal in dimension with a borderline free wall dimension. There is a diffusely hyperechoic endocardium consistent with fibrosis. Mild LV chamber dilation. The papillary muscles are mildly remodeled. The left atrium is mildly dilated and bulbous in appearance. The right atrium is mildly dilated. The right ventricle appears prominent. The MPA appears normal. The mitral valve is normal with mild central MR. Blood flow through both the LVOT and RVOT is normal in velocity. Mild to moderate TR. Normal velocity. Scant/small volume pericardial effusion seen. No pleural effusion. No obvious cardiac tumors.

CARDIAC CHART

FELINE CARDIAC PARAMETERS	BODY WEIGHT (kg)	HR (BPM)	IVSd (cm) <small>(Moise, Pipers)</small>	LVIDd (cm) <small>(Moise, Pipers)</small>	LWVd (cm) <small>(Moise, Pipers)</small>	FS (%)	EF (%)
NORMAL PARAMETER	-----	150-240	3.5-0.55	<2 (mean 1.5)	3.5-0.55	35-67	80-100
PATIENT	6.4	190	0.4	2.0	0.58	45	80
FELINE CARDIAC PARAMETERS	LA/AO <small>(Boon)</small>	LA/AO HEART BASE (Swe) <small>(Abbott)</small>	LA 2D short axis Base view (cm) <small>(Abbott)</small>		LVOT VEL (m/s)	RVOT VEL (m/s)	E max (m/s)
NORMAL	<1.5	<1.3	<1.2		<1.6	<1.3	<0.9
PATIENT	NM	1.45	1.5		1.4	1.1	NM

Adapted from June Boon, Veterinary Echocardiography, 1998

Abbott J & MacLean H JVIM 2006;20: 111-119, Moise et al. Am J Vet Res 47:1476, 1986. Pipers et al. Am J Vet Res 40:882, 1979.

INTERPRETATION OF THE FINDINGS & FURTHER RECOMMENDATIONS

The finding of any degree of biatrial enlargement in the face of minimal LV wall changes is most consistent with Unclassified Cardiomyopathy (UCM), however some prior infectious or inflammatory insult to the myocardium cannot be definitively ruled out. There is also significant LV remodeling and fibrosis which indicates diastolic dysfunction. Small leaks are noted in the mitral and tricuspid valves; however, these are largely hemodynamically insignificant. Serial echocardiography will be necessary to confirm the diagnosis and assess for progression.

Regardless of categorical classification, the finding of biatrial dilation is concerning for progression in the future. The small volume pericardial effusion is notable as well, and two broad possibilities for its origin could be argued. First with mild biatrial dilation this may be due to congestive heart failure, albeit most CHF occurs with severe LA dilation and associated clinical signs of tachypnea/dyspnea (this patient is asymptomatic). An alternative explanation would be that this patient has subclinical disease and an unrelated non-cardiac origin of the effusion, **particularly in light of the anemia**. At this time, I would consider this more likely although difficult to confirm. All possibilities should be ruled out, including neoplastic origin or fluid overload (no mention of iatrogenic fluid administration in the history). A Lasix trial can be initiated should no other systemic issues be identified that may make CHF more or less likely.

Pending progression, patient will always remain risk for CHF and/or development of blood clots in the future. Monitoring of sleeping respiratory rates (SRRs) at home is recommended as the best way to screen for recurrent CHF at home. High risk for fluid overload if utilized in the future, and cautious up-titration with SRR monitoring is advised.

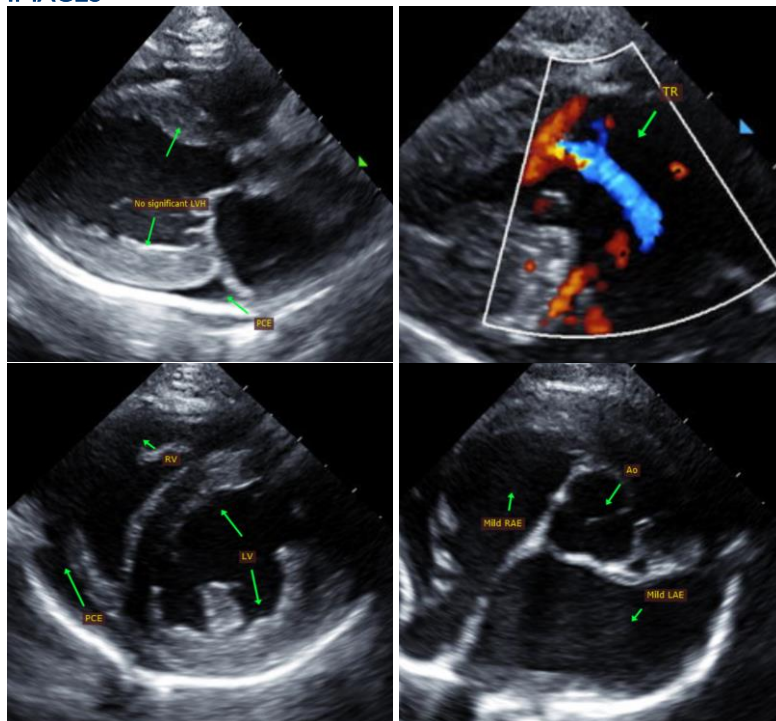
Steroids should be ideally avoided in this case pending further evaluation. If a neoplastic process is contributing, then these may actually be indicated. The first step would be assessing response to diuretic therapy.

PLAN

Consider a Lasix trial as discussed if no systemic issues are identified (1-2mg/kg PO q12h for 1-2 weeks and reassess effusion). If resolves, continue long term with addition of Plavix and Pimobendan. If no change, discontinue. Full systemic evaluation should be considered.

A recheck echocardiogram is recommended in 6 months to assess progression, sooner if any associated clinical signs develop.

IMAGES



The information and recommendations provided are based on the images presented by the referring veterinarian. No evaluation can be communicated regarding pathology that was not visible in the image/video clips provided.

Thank you for this referral. This report was generated using transcription software, and minor dictation errors may be present. If the clinical or image interpretation does not parallel your findings or if I can be of any further assistance, please contact me.

Maggie Machen Lamy, DVM
Diplomate of the American College of Veterinary Internal Medicine (Cardiology)
info@sonopath.com